

The Inman Aligner: A progressive approach to smile design - Part 2

By Dr Tif Qureshi



“Patients who desire a more traditional smile makeover can achieve beautiful results in a manner that allows them to make choices along the way...”

The following article is Part 2 in a series discussing the use of the Inman Aligner as a tool for minimally invasive cosmetic dentistry.¹ The first article (published in November/December 2010) demonstrated that standalone treatments offer patients an alternative to both fixed braces, which are unsightly and have long treatment times; and to expensive clear aligner treatments in suitable cases.

This article will demonstrate that patients who desire a more traditional smile makeover can achieve beautiful results in a more progressive manner that allows them to make their choices along the way. This often results in virtually no removal of tooth structure and a treatment result with the responsibility of decision-making shared between dentist and patient.

Moreover, the subject matter of this article could potentially start one of the most controversial debates in cosmetic dentistry for years. We are not only discussing a radically different approach to smile makeovers, but critically a sharply different approach to the traditional methods of planning smile design.

What would you choose?

Patients entering cosmetic practices are often assessed at the initial consultation. They have digital photographs taken and perhaps study models are made. Normally, dental imaging software is used to show patients what can be achieved. These ingenious programmes (see www.snapdental.com/AUST) can help patients realise what is possible. Naturally, care must always be taken when promising treatment results that are viewed digitally.

While computer imaging can be a very powerful tool to help the patient see the potential in his/her smile, I believe it also can make a patient focus on a certain prescribed goal that may not be the only way of satisfying his/her wishes. Dentists using imaging would ideally create a set of five to ten different outcomes of varying degrees of improvement to allow the patient to make a more informed decision. While ideal, it is not certain that dentists actually present different levels of treatment to their patients digitally. Even if they were able to see various images of their teeth, it can still be difficult for a patient to really see and feel the

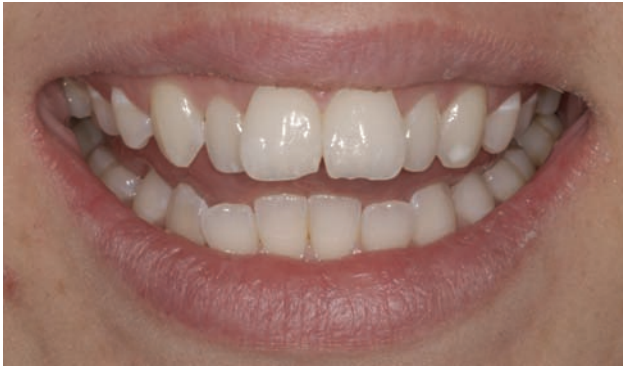

Figure 1. Smile View before treatment.

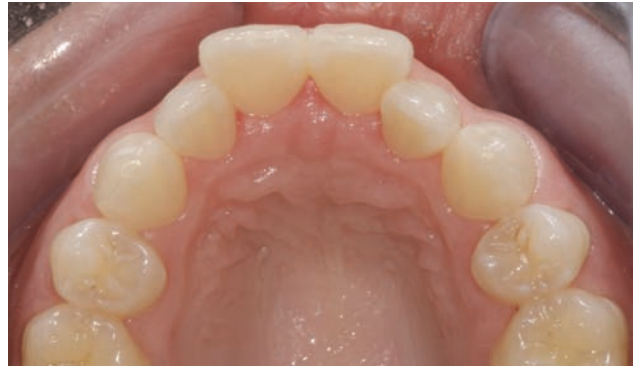

Figure 2. Occlusal view before.

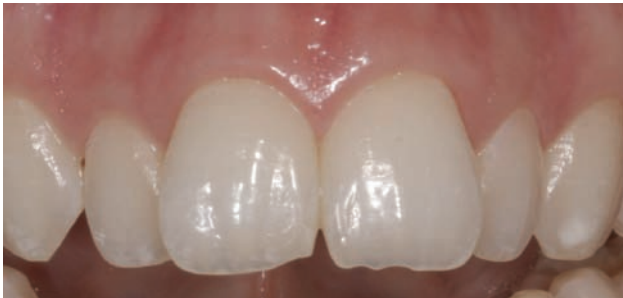

Figure 3. Close up view before.

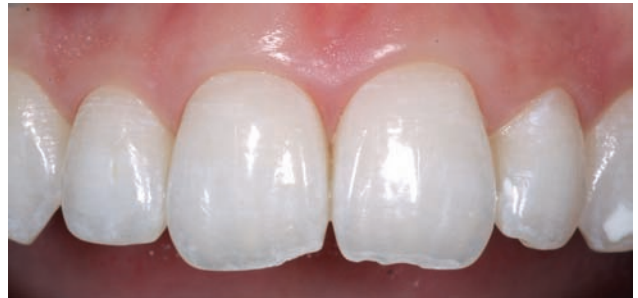

Figure 4. Close view after Inman Aligner and whitening at week 9.

suggested changes in their mouth. One can question the ethics of allowing patients to commit to a potentially irreversible procedure based on 2-D photographs.

Three-dimensional wax-ups can also be very useful at this stage. If a patient is keen on the image, going to an additive wax-up can sometimes allow for a direct preview try-in using a silicone stent taken from set-up. Temporary material of variable shades can be tried in directly, without any bonding to allow the patient to see the proposed outline, form and overall aesthetics.

Despite this, veneers are often used to treat alignment issues and it is very difficult for patients to appreciate the alignment of their own teeth with wax-up or imaging. By approaching these cases with a different protocol in mind, a dramatically less invasive treatment plan becomes evident.

The first step is to look at the patient's tooth alignment. Misaligned teeth often cause issues in gum heights, line angles, light reflections, shades and tooth length. Correcting the misalignment first can create a completely different perception of the apparent problems. Next, the teeth should be bleached. This can be done either immediately after the teeth have been aligned or preferably simultaneously. After alignment and bleaching, edge bonding (we term this the ABB concept) should be offered to improve the incisal edge outline.

This combination of treatments also works well because the Inman Aligner is a removable appliance and only needs to be worn 16 to 18 hours a day. This means simultaneous bleaching is very possible and straightforward. A recent study from Sweden indicates a cost-benefit advantage of treating patients with removable appliances in general dental clinics, rather than with fixed appliances at specialist orthodontists.² The conclusion of this study is significant, since a popular choice amongst aesthetic dentists in the UK is removable orthodontics.

The cases outlined here highlight patients who, either at the start of treatment or for years, had originally wanted veneers and had a specific result in mind that only veneers could have offered quickly. They were all concerned about the degree of preparation required, so undertook alignment first. Then, part of the way through, started bleaching and very quickly changed their minds about what they wanted once they saw their own teeth improve.

Case 1 (Figures 1-8)

Laura was concerned about her very prominent central incisors. She wanted to have them straightened and had considered veneers. She had ruled out conventional orthodontics and invisible braces because she wanted a quick treatment and did not want anything stuck to her teeth, which is the reason that she had refrained from orthodontic treatment. Several years ago, she may well have had veneers placed.

On viewing her teeth before the occlusal photograph, it was quite clear that this would have involved massive preparation of the upper central teeth. Preparation would have been well into dentine and may have even involved elective endodontics. Her lateral teeth would have needed little preparation, but the emergence profiles would have been poor, creating unrealistic aesthetics and a possible periodontal risk later on. Instead, the alignment was completed with an Inman Aligner in ten weeks. Her treatment sequence is detailed below.

BACD-style digital photographs were taken and the amount of crowding was calculated using an electronic crowding calculator, which can also be done by arch evaluation of the patient's study models. We measured the ideal curve and subtracted this measurement from the total mesio-distal widths of the teeth being moved.³ The results showed that there was only 1.6 mm crowding. This seemed less than one would have expected; the

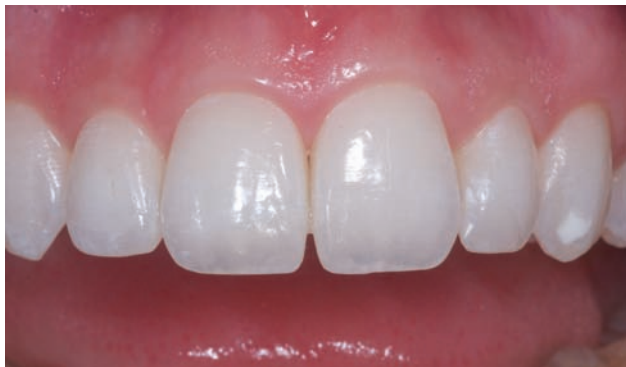

Figure 5. Close view after ABB at week 9.

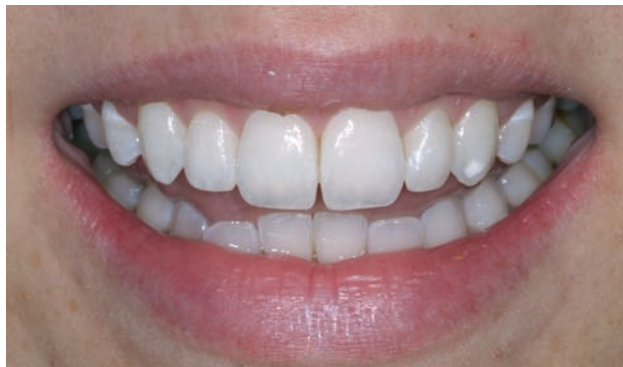

Figure 6. Smile view after 9 weeks.

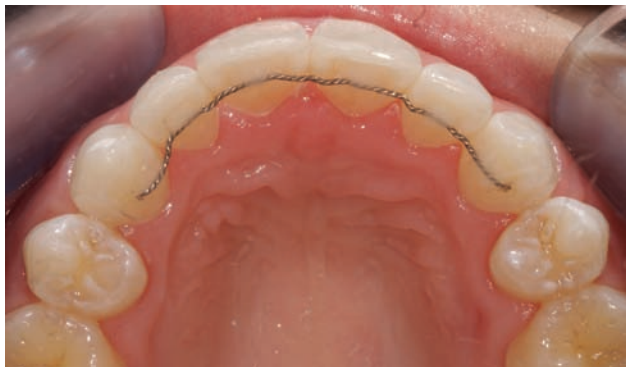

Figure 7. Occlusal view after.



Figure 8. Full face view after.

reason for this was that because the laterals were being pushed out, the arch was being expanded, thus creating space.

It was clear from the photographs that despite the obvious crowding, there was some less obvious irregular tooth wear. It was important to indicate this to the patient, as this would become more evident once the misalignment had been corrected. The

patient was quoted for three incisal composite tips. She opted for an Inman Aligner with an incorporated expander. These expanders are a very handy way of creating extra space either to treat cases that are more complex or to use instead of performing interproximal reduction (IPR).

In this case, no IPR was performed. We planned to get nearly all space by using the midline expander. The patient was instructed to turn the midline screw once a week after one week of wear. Each turn is a quarter of a revolution and equates to 0.25 mm. At week six, bleaching was started with soft rubber sealed trays. After nine weeks, the patient had expanded 1.8 mm and her teeth were in alignment (As a rule, less than 2.5 mm expansion with an incorporated expander is easily tolerated).

Looking at her post-alignment result, the golden proportion, gingival heights and axial-inclinations had improved dramatically, all without a handpiece being picked up and in the space of nine weeks. What was very clear to the patient at this point was that she only needed some simple bonding to improve the incisal edge outlines. Without the use of an anaesthetic, the edge outlines were prepared with very slight roughening of the edge, bonding of hybrid composite on the load bearing edge and a micro-fill on the facial surface. The edges were then polished.

The patient was thrilled with the result we achieved using an Inman Aligner and some simple bonding. She described that

when she had once considered having veneers, she had hoped for a similar result. There are still minor imperfections, but, in my opinion, these contribute to her natural beauty.

There is a stark contrast between the treatment selected and the potential treatment approaches in this case. Where once a patient, who refused orthodontics, would have consented and received highly aggressive tooth preparations to achieve correct alignment with veneers, now a removable aligner and some simple bonding were able to achieve a similar and arguably better result in less than three months with not a micrometer of tooth reduction needed.

Case 2 (Figures 9-17)

This young lady had been attending my practice for some time and was aware of porcelain veneers, having seen our previously advertised cases. We had spoken about the aesthetic benefits of veneers years before. However, on reviewing her case, it was clear that we could improve her alignment dramatically with an Aligner in a short period.

We took an occlusal image of her anterior teeth and outlined the amount of tooth structure that would have to be removed to produce veneers that would look aesthetic. It was immediately apparent to the patient that alignment of her teeth would offer a possibly better treatment outcome. Her case was suitable for an Inman Aligner and as only 2.5 mm crowding was present, this meant it could be treated quickly and simply.

Her Inman Aligner was fitted and IPR performed progressively over three visits. At week eight, upper and lower bleaching trays were constructed even though her alignment was not yet complete. Home whitening was begun with clear and concise instructions. We used rubber trays with a deep seal cut into the

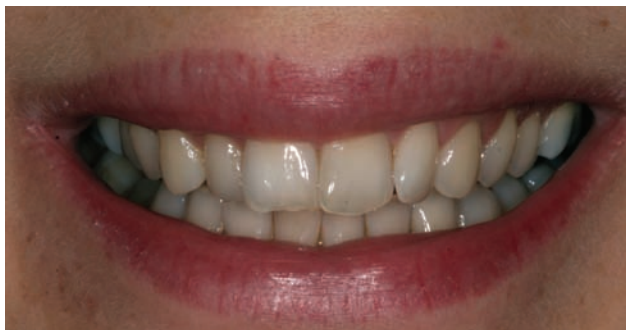

Figure 9. Before smile view.

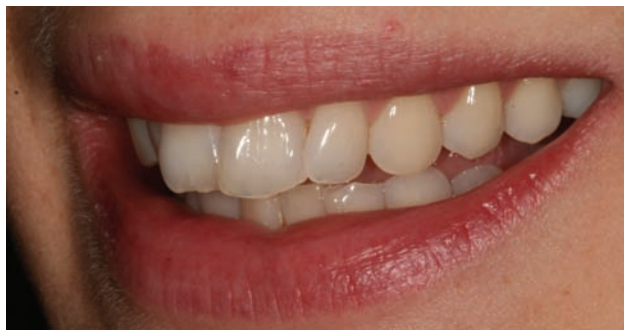

Figure 10. Before side smile view.

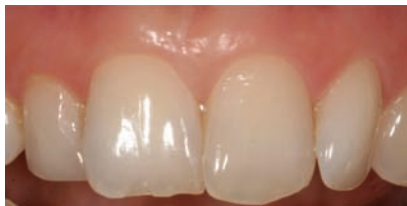

Figure 11. Before close up view.

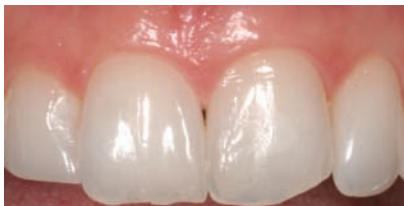

Figure 12. After Inman Aligner and whitening at 10 weeks.

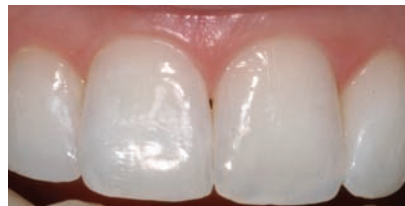

Figure 13. After no-prep edge bonding at week 12.

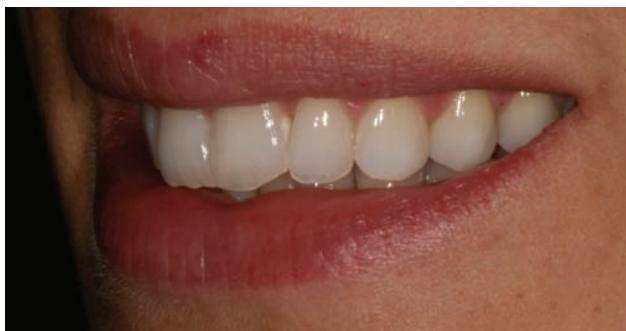

Figure 14. Side smile after alignment and whitening.

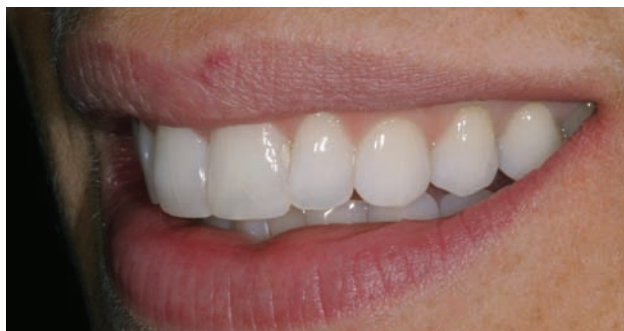

Figure 15. Side smile after edge bonding.

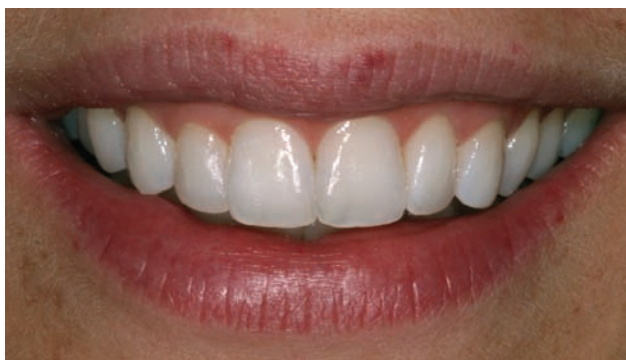

Figure 16. Smile view after ABB.



Figure 17. Full face view after.

model to create a tight dam effect. Over two weeks, her teeth whitened nicely and at week ten, she returned for a review.

Interestingly, the patient's perception of her smile had changed dramatically. Owing to the improved line angles, whiter teeth and balanced gum heights, her eyes were now only drawn to the irregular outline caused by chipping and differential wear.

The patient then enquired about fixing the edges. We offered to bond the incisal edge with virtually no preparation. A hybrid composite (Tetric Flow, Ivoclar Vivadent) was placed palatally and incisally with a micro-fill on the facial surface. This was done in B0 and B1 shades to match the bleaching. The patient was delighted with the result and a wire retainer was bonded immediately.

Despite some clear deviations from her ideal simulated smile, the patient explained that she felt her smile after alignment was better than she had imagined her veneers would have been. Had veneers been placed, we could perhaps have corrected the golden proportion more fully, balanced the zeniths, improved the canine outlines, widened the buccal corridors, etc. However, that was clearly not what the patient desired. Should she later decide that she does need further improvements, we can proceed with already straightened teeth. The ABB smile design is progressive and not sudden or rushed. In this manner, the patient is given the opportunity for decision-making in his/her treatment and the responsibility in choice is shared.

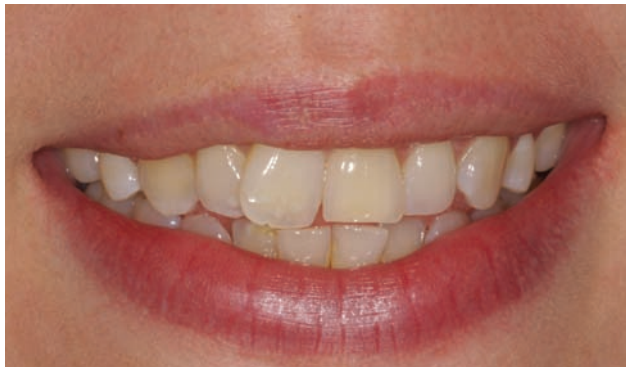

Figure 18. Smile view before.

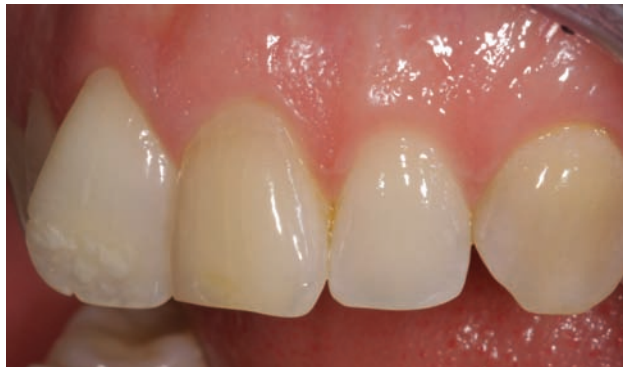

Figure 19. Close left side view before.

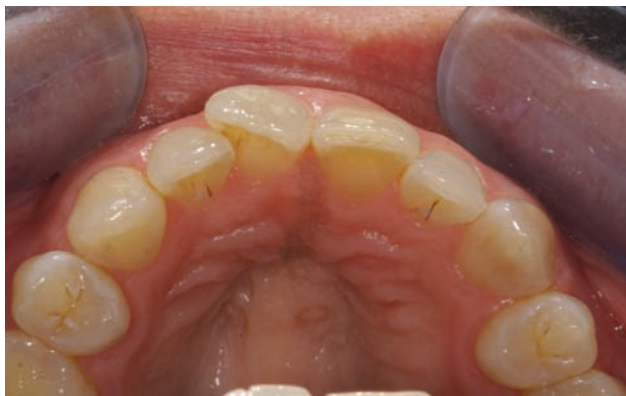

Figure 20. Occlusal view before.

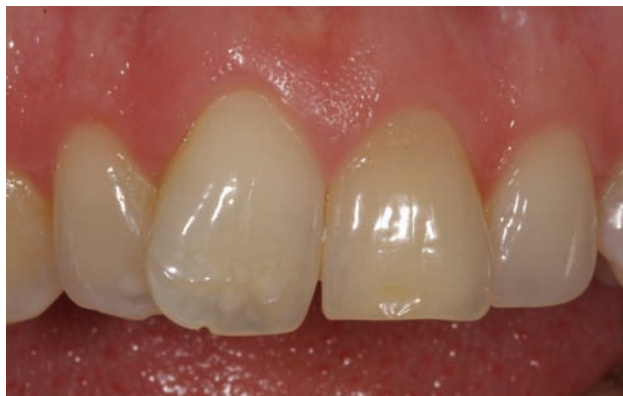

Figure 21. Close view before.

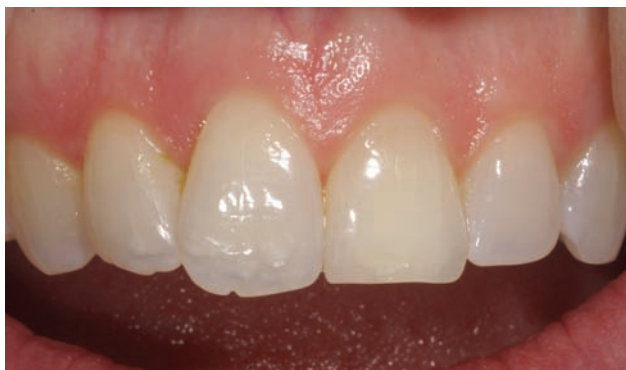

Figure 22. Close view after alignment and whitening at week 10.

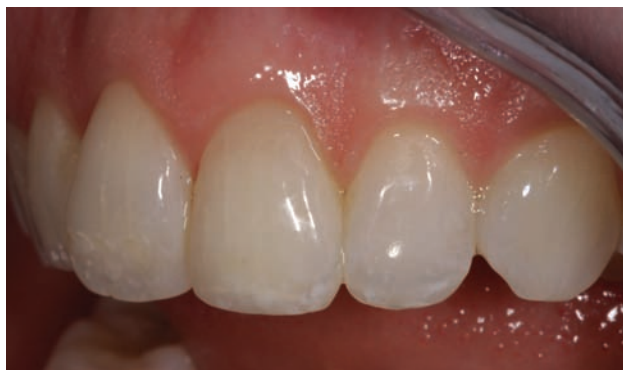

Figure 23. Close right side view after Edge bonding.

Case 3 (Figures 18-26)

This patient presented with what she described as a “wonky smile”. She had previously looked into the possibility of having porcelain veneers placed so understood some of the aims of smile design. However, on studying her teeth, it became clear that there was potential to pre-align first. Her upper right central was mesially rotated by approximately 30° and her laterals were slightly in-standing and mesially inclined. Furthermore, she had fairly stained teeth, with the canines two shades darker than the centrals.

On examining the occlusal view, the patient became aware of the extent of aggressive tooth preparation that would be required to place a veneer. She understood that her teeth needed to be aligned first before we decided on the next step in design.

An Inman Aligner was used over the period of eleven weeks to de-rotate the front tooth and to tip out the laterals. At week eight, bleaching was begun using 35- to 45-minute a day H₂O₂ gels.

Simultaneous whitening is a very attractive part of aligner treatment, as it helps with patient motivation. After alignment, the case was re-examined. Once her teeth had been straightened, it became evident to the patient that her problem concerned edge shape, which had actually worsened with alignment owing to differential wear. In fact, the left central was 2.5 mm shorter than the right. It was very clear to the patient that only these incisal edges needed building in order to achieve the smile she desired.

For placement of the incisal edges at week twelve, no local anaesthetic was administered. Other than slight roughening of the worn incisal edges of the upper left 1 and 2, no other preparations were needed. A tetric hybrid composite (Tetric Flow, Ivoclar Vivadent) was built up free-hand on the incisal edge and palatal surface to match the outline of the other central. A small amount of white opaquer was dotted in to match the facial surface and

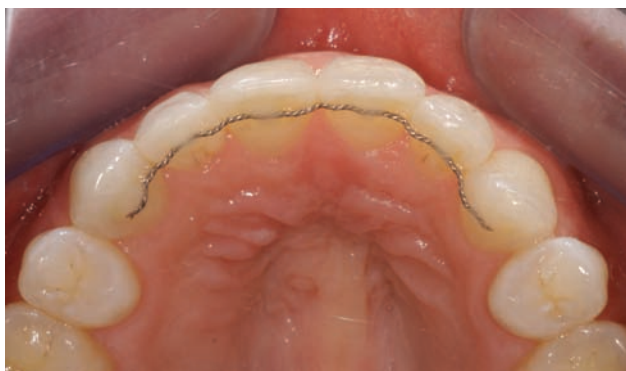


Figure 24. Occlusal view after.

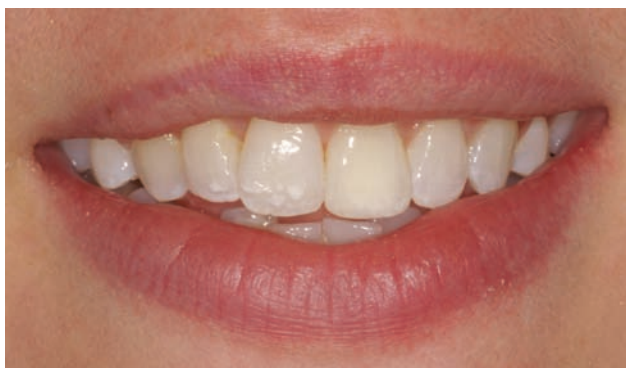

Figure 25. Smile view after ABB at 12 weeks.

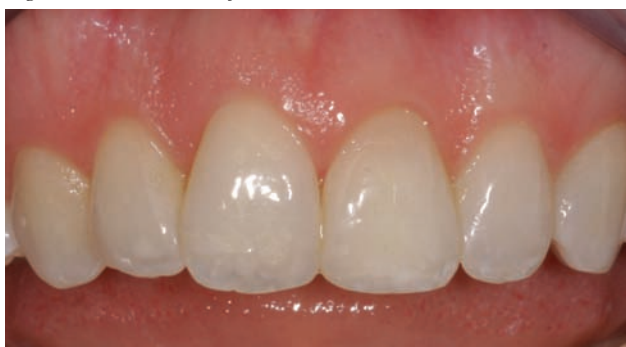

Figure 26. Close view after ABB at 12 weeks.

was simply filled with a nano-hybrid composite (Venus Diamond, Heraeus) for high polish. The composite was polished vertically using rubber sticks (PoGo, DENTSPLY DeTrey) to try to blend in with surface anatomy to mask the join. The process was repeated on the lateral.

The patient was held in retention using her aligner and an impression was taken for a wire retainer to be fitted two weeks later. It was especially nice to retain the natural aesthetic characterisation of this patient. Ceramic work, as beautiful as it can be, would certainly have changed her appearance more – some may say for the better, but that was not what the patient actually wanted. She wanted her own teeth to have correct length and look straighter and whiter.

Shared responsibility of treatment

The ABB concept can truly be described as minimally invasive. At the same time, it actively involves the patient in the treatment, giving him/her a feeling of being in control and taking responsibility for his/her treatment. This has been proven to be of great significance when measuring patient satisfaction of treatment results.⁴

There are many anecdotal stories about patients who had technically beautiful veneers placed but found that these simply did not meet their desires. The problem is that even with no-preparation veneers, an irreversible procedure has been undertaken and this has been done mainly based upon the treating dentist's opinion, with the patient having very little input.

In my experience, every patient that I have treated according to the ABB concept has accepted the result happily, even though technically it might not be perfect from a smile design point of view. Nowadays, with rising levels of litigation, one would have to question the wisdom of selecting a treatment path that could result in conflict over one in which the patient participates in key decisions and sees his/her own teeth improve.

I believe this approach firmly sits alongside minimally invasive cosmetic dentistry core principles, which recommend a more minimally invasive and patient-led approach.

Conclusion

I understand the controversy in challenging the traditional approach to smile design, but the new mantra of progressive smile design is vital when we are looking to give our patients what they actually want. Previously, pre-whitening was always a way of giving our patients an alternative view of their teeth. Now, and more significantly with alignment techniques, patients can make their own decisions and massively reduce the risks by breaking down the process of a smile makeover into stages and reassessing at each point.

With ABB, it is possible to align, whiten and bond a case in less than twelve weeks, which previously might have required eight to ten veneers, four times the cost and significant tooth preparation. Thus, a dramatic contrast in pathways has been created. If a patient is happy after alignment, whitening and minimal bonding, then this has to be viewed as a success. This UK technique is now a significant new treatment discipline in itself and cosmetic dentistry will be better for it. After all, what would you choose to have?

References

A full list of references related to this article is included in the online version or can be supplied on request.

This article originally appeared in cosmetic dentistry_beauty & science Vol. 4, Issue 4/2010. It is published with permission by Dental Tribune International GmbH. © 2010 Dental Tribune International GmbH. All rights reserved.

About the author

Dr Tif Qureshi is the President Elect of the British Academy of Cosmetic Dentistry. He is also the Global Director of Education for Inman Aligner Education through Straight-talks seminars (www.straight-talks.com).